

EXPERT  
REVIEWS

# PRECICE intramedullary limb lengthening system

Expert Rev. Med. Devices Early online, 1–19 (2015)

## Dror Paley

The Paley Advanced Limb Lengthening Institute at St. Mary's Medical Center, 901 45th Street, Kimmel Building, West Palm Beach, FL 33407, USA  
Tel.: +1 561 844 5244  
Fax: +1 561 844 5245  
drorpaley@gmail.com

The PRECICE® Intramedullary Limb Lengthening System (Ellipse Technologies Inc., CA, USA) is a remotely controlled, magnetically driven, implantable limb lengthening intramedullary nail system. It has both CE mark and US FDA clearance for its first- (2011) and second-generation (2013) implants. It is indicated for the treatment of limb length discrepancy and short stature. It has been used worldwide in over 1000 cases. Its reported and published results in over 250 cases has been excellent with less pain and lower complication rates than with external fixation methods or previous implantable nail systems.

**KEYWORDS:** congenital femoral deficiency • distraction osteogenesis • fibular hemimelia • intramedullary nails • leg length discrepancy • limb length discrepancy • magnet • noninvasive • PRECICE®

Ellipse Technologies (Irvine, CA, USA) developed the PRECICE nail with a team of surgeons (including myself) headed by Dr. Stuart Green. They used the same mechanism that they had developed for their spinal growing rod called 'the MAGEC System' [1]. There is a magnetic metal spindle that is connected to a series of gears (FIGURE 1). The gears are connected to a coupling, which is connected to a threaded drive shaft. The mechanism is activated by an external remote control (ERC) device (FIGURE 2A). The ERC employs two motor-driven rotating magnets to magnetically couple to and rotate the magnetic metal spindle (FIGURE 2B). Facing the ERC in one direction causes the nail to lengthen, while facing it the other direction would go in the reverse (shortening) direction. PRECICE is the second FDA-cleared implantable lengthening nail device (July 2011) and the first one to have bidirectional control (lengthening and shortening). I had the privilege of implanting the first PRECICE nail in the USA on 1 December 2011.

The Ilizarov procedure remained the best option for limb lengthening until the introduction of these new nails in the 1990s. It was thought that with this new technology the complications related to limb lengthening would be greatly diminished. Intramedullary nail techniques are not without complications, which may include nonunions, nerve injuries, nail fractures, joint contractures and other serious complications [2–10]. External

fixation approaches to limb lengthening remain the gold standard. Experience with implantable limb lengthening have made evident that the complications of limb lengthening can be divided into two categories, device related and distraction related. The device-related complications are very different for external versus internal lengthening devices. The high complication rates related to pin tract infections, joint stiffness and contractures due to tethering of the muscles by the pins, and large pin tract scars, do not occur with implantable devices. The complications related to distraction are similar between external and internal lengthening methods. These complications include premature consolidation, delayed and failed bone formation, nerve stretch injury, muscle contractures and joint subluxation. The reduced device complications and even some reduced distraction complications (e.g., axial deviation) have made the switch to implantable devices very attractive and have created a market for these technologically advanced devices.

## Body of review

### Overview of the market

The indications for limb lengthening are for the treatment of limb length discrepancy of the lower or upper limb and for stature lengthening. The indications for leg lengthening are for the treatment of leg length discrepancy or short stature. Unilateral limb lengthening is used to equalize limb length in



**Figure 1. Photograph of tibial nails: PRECICE 1 (P1, left) and PRECICE 2 (P2, right).** Note the three welds in P1 and no welds in P2.

the treatment of limb length discrepancy. Bilateral limb lengthening is used for increasing height and restoring body proportions in patients with dysplasias (e.g., achondroplasia and hypochondroplasia) and other genetic conditions (e.g., Turner's syndrome), for the treatment of height dysphoria in patients with short stature and for increasing height for cosmetic reasons.

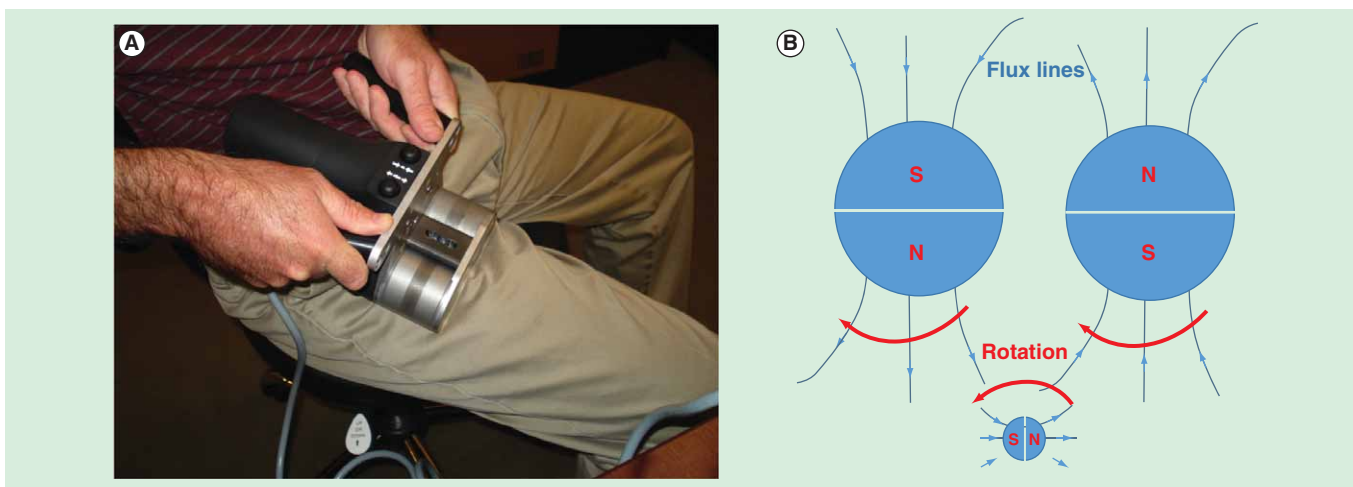
Leg length discrepancy can be due to congenital, developmental or posttraumatic causes.

Developmental or posttraumatic causes may include growth plate arrest, malunion, nonunion, bone loss from open fractures, osteomyelitis or tumor. Minor leg length discrepancy is prevalent, with 23% of the general population possessing a discrepancy of at least 1 cm. The prevalence of leg length discrepancy where a corrective device is required is approximately 1 in 1000. More severe discrepancies such as congenital femoral deficiency and fibular hemimelia are rare and complex congenital disorders of the lower limb with an incidence of approximately one in 50,000 live births for congenital femoral deficiency [11–13] and between 7.4 and 20 per million live births for fibular hemimelia [14–16].

Short stature is a common feature of most dysplasias and musculoskeletal syndromes. Achondroplasia is the most common dysplasia and occurs in 1:40,000 births. Constitutional short stature is defined as under the 5th percentile for height (5% of the population). Height dysphoria is a well-known condition also referred to as height neurosis. It is a very common condition although no accurate statistics exist as to its prevalence. Most patients with height dysphoria are over the 5th percentile in height. Height dysphoria represents a body image anxiety disorder, which is generally unresponsive to psychotherapy. Lengthening for height dysphoria is considered cosmetic or aesthetic lengthening.

Limb lengthening for limb length discrepancy is a well-accepted indication for treatment. Nevertheless, its market is relatively small. Similarly, stature lengthening for the treatment of dysplasias, although more controversial, is also a well-accepted indication for treatment, again with a relatively small market.

Stature lengthening for cosmetic reasons is a very controversial indication for treatment. Nevertheless, there is a growing demand for such treatment by the population. There are numerous social network websites that serve to voice the interest and demand for such treatment. As such it is a huge




**Figure 2. External remote control. (A)** Photograph of external remote control device being applied to the thigh for femur lengthening. **(B)** Illustration of how rotation of the 2 external remote control magnets (big circles) cause the nail magnet (small circle) to rotate through their magnetic fields.

untapped market. A small but growing number of cosmetic stature lengthening centers have sprung up around the world to service this demand.

The concept of cosmetic stature lengthening is foreign to most orthopedic surgeons. Unlike our plastic surgery colleagues, we have no tradition of cosmetic or aesthetic surgery. Orthopedic surgery is founded on the principles of treatment of pain, disability and deformity. We use our surgery to treat or prevent pain and disability. Our surgery is funded by reimbursement by third-party payers since it is not considered cosmetic.

With the decreasing reimbursement for surgery, the allure of a cash-paying cosmetic surgery practice will attract many orthopedic surgeons in the near future. The cosmetic market may become the largest indication for implantable limb lengthening. Until now the external fixator has been the gold standard for limb lengthening. Most orthopedic surgeons shy away from external fixation and as such it has become the realm of a small group of orthopedic specialists. The external fixator has also kept patients away from this treatment. Now that the surgery is both simpler for the surgeon and less complicated for the patients, we can anticipate an increase in the number of surgeons who take up limb lengthening and patients who are keen to have it done. The number of implants used for the treatment of leg length discrepancy and dysplasias will, in the future, be far outnumbered by the number used for cosmetic stature lengthening. Needless to say each cosmetic case represents two implants compared to one for each leg length difference. While limb length discrepancy (LLD) patients often have staged lengthening over the course of their childhood, stature patients often have a second pair of lengthening for their other segments (e.g., two femurs and then two tibias) still outnumbering the LLD indications. Unfortunately, the ease of application of the device is misleading. While the surgery is relatively easy and can be carried out by most orthopedic surgeons, the postoperative follow-up and the learning curve for the treatment of distraction-related problems and complications is quite steep. Most orthopedic surgeons are not knowledgeable in the postoperative management of the limb lengthening patient. As such we may anticipate a large number of complications created by surgeons knowledgeable in the insertion of nails but unprepared for the management of the limb lengthening process. Since the use for stature is so potentially lucrative, this sector of the market may grow precipitously but may also be subject to significant abuse.

External fixation defines the existing market for limb lengthening. Implantable lengthening nails are indicated for the same market currently occupied by limb lengthening external fixators. The indications for their use are the same: limb length discrepancy and short stature. Implantable nails are currently limited by anatomy, length, diameter and limited ability to correct deformity especially in children and the short bones of dysplastic patients. In the USA, the only FDA-approved device was intramedullary skeletal distractor (ISKD) (Orthofix Inc, Lewisville, TX, USA). It was introduced to the market in 2001 and was finally withdrawn from the US market in 2011. In Europe,




**Figure 3. Radiograph of the actuator of PRECICE showing its different parts.** The magnet is connected to a series of three gears (gear box) that are connected to a coupling which links to the lead screw. The threaded drive shaft (lead screw) lengthens or shortens the smaller diameter tube of the nail relative to the bigger diameter tube.

Fitbone, Phenix and Albizzia all on very limited releases were the only other alternatives. Phenix is now off the market due to the untimely death of Arnaud Soubieran its inventor. It is due to resurface (perhaps in 2015) as a product called Novus from Smith and Nephew Orthopedics (Memphis, TN, USA). Fitbone (Wittenstein, Igersheim, Germany) is distributed to a small number of surgeons under the direct approval by Dr. Rainer Baumgart. The rationale for approval is supposedly based on experience and limited by number of centers per country. This decision seems very arbitrary and as a case in point, I was unable to receive approval by Dr. Baumgart for its use. Fitbone also has the distinction of being the most expensive implantable nail. The modified Albizzia, referred to as the Betz Bone, and the Guichet nail are only used by these two namesake surgeons and are not available for commercial distribution. Thus, PRECICE introduced both in the USA and internationally in 2011 has become the only commercially available remote controlled implantable limb lengthening device.

### Introduction to the device

#### Device description

PRECICE is a telescopic intramedullary locking nail. The mechanism has a rare earth magnetic metal spindle that is connected to a series of three planetary gear clusters (FIGURE 3). Each gear cluster produces a reduction of 1/4 for a total reduction of 1/64 between the magnet and the drive screw. There is a coupling between the gears and the drive screw with a safeguard



**Figure 4. Radiograph before distraction (0 mm) and after distraction of 1 and 2 mm.**

(like a clutch) built in to avoid breakage in the face of extreme torque resistance. The mechanism (actuator) is activated by an ERC device (FIGURE 2A). The ERC employs two motor-driven rotating magnets to magnetically couple to and rotate the magnetic metal spindle (FIGURE 2B). The ERC performs 30 revolutions per minute. It takes 7 min and 210 revolutions to achieve 1 mm of lengthening. Facing the ERC in one direction causes the nail to lengthen, while facing it the other direction would go in the reverse (shortening) direction.

#### PRECICE nail & locking screws

The first generation of the Ellipse PRECICE Limb Lengthening System is composed of the PRECICE intramedullary nail, locking screws, implantation tools and accessories, and an ERC. The implantable nail is supplied sterile by  $\gamma$  radiation and is available in tibia and femur models with diameters of 10.7 and 12.5 mm, stroke length of 65 mm, overall starting lengths of 230–355 mm, and distal screw hole patterns to accommodate a variety of patient anatomies. Likewise, the locking screws are available in two different diameters and a variety of lengths from 20 to 75 mm in 5 mm increments.

The first-generation PRECICE (PRECICE 1) is modular such that the intramedullary limb lengthening actuator component had to be assembled in surgery to an extension rod of different length and anatomical shape. The length of the intramedullary limb lengthening actuator is fixed, while the extension rods varied in length. The intramedullary limb lengthening actuator including its rare earth magnet, telescoping lead screw/nut assembly and gearing were housed in a rod segment that was welded above and below to the rest of the nail housing. In total, there were three welds in this unit and one connection to the extension rod via set screw. Extension rods, locking screws and reusable accessories are supplied nonsterile and must be sterilized prior to use. The second-generation Ellipse PRECICE 2 Limb Lengthening System released in November 2013 is composed of the PRECICE intramedullary nail, locking screws, implantation tools and accessories, and an ERC. The modified implantable nail is

supplied sterile by  $\gamma$  radiation and is available in tibia and femur models with diameters of 8.5, 10.7 and 12.5 mm, stroke lengths of 50 and 80 mm, overall starting lengths of 195–365 mm, and distal screw hole patterns to accommodate a variety of patient anatomies. Likewise, the PRECICE locking screws are available in different diameters and a variety of lengths ranging from 20 to 75 mm. The PRECICE locking screws and implantation instruments and accessories are supplied nonsterile and must be sterilized prior to use. The PRECICE nail is surgically placed in the intramedullary canal of the femur or tibia. The femur models offer piriformis, trochanteric and retrograde entry models. The metal in contact with the patient's body fluids and bone is composed of medical grade titanium alloy (Ti-6Al-4V). The rare earth magnet and gears are sealed from body fluid contact.

#### External remote control

The ERC provides a noninvasive method for precisely distracting the nail at defined intervals. The ERC includes two permanent magnets that are rotated by a motor which is electronically powered. When the ERC magnets are rotated in proximity (less than 5.5 cm) to the PRECICE nail, the rare earth magnet in the nail turns and the distracting rod either lengthens or shortens the intramedullary nail depending on the direction of rotation of the ERC magnets. The first use of the ERC is in the operating room to test the functionality of the nail mechanism. A 1-mm test distraction is performed and confirmed radiographically. Postoperatively after a latency period ranging from 0 to 7 days, the nail is lengthened daily by the patient (or their caregivers) according to the daily prescription set by the treating physician (FIGURE 4).

#### Implant technique (PRECICE 2)

##### *Surgical technique femur*

Step 1: The patient is positioned supine on a radiolucent operating table. A radiolucent bump (usually a folded towel or sheet) is placed underneath the ischium on the operative side. This allows good visualization of the hip on both antero-posterior (AP) and cross table lateral views.

Step 2: Using the image intensifier (fluoroscopy), the tip of the level of the greater trochanter is marked on the skin. Knowing the length of the nail to be used for the surgery, a ruler is used to mark the distal end of the nail. For retrograde nailing, measure from 1 cm proximal to the intercondylar notch.

Step 3: The level of the osteotomy is determined by knowing the amount of distraction planned. One must plan to end up with the larger diameter of the nail always engaged on both sides of the distraction gap at the end of lengthening. Assuming one wants to have 2 cm of the larger diameter of the nail engaged, then add 2 cm plus 3 cm of the smaller diameter nail, which is exposed plus the distraction amount. This total measured from the distal end of the nail represents the level of the desired osteotomy that will leave at least 2 cm of the larger diameter of the nail always engaged in cortical bone on the opposite side of the distraction gap.

Step 4: Make a 1-cm incision laterally at the level of the osteotomy. Drill holes using a 4.8-mm drill bit. I prefer one entrance and three exit holes, anteromedial, posteromedial and medial. Then make two more drill holes anterolateral and posterolateral at the level of the other holes. These six holes will serve to vent the canal from fat emboli and to allow the reamings that extrude through the holes to auto-bonegraft the osteotomy site.

Step 5: Insert a Steinmann pin into the piriformis fossa for adults or adolescents with closed growth plates. For patients with an open proximal femoral growth plate, insert the Steinmann pin into the tip of the greater trochanter. For retrograde nailing, insert the Steinmann pin at the center of the intercondylar notch on the AP and at the distal end of Blumensaat's line on the lateral.

Step 6: Expand the starting point with a 10-mm anterior cruciate ligament reamer.

Step 7: Insert a beaded guide rod down the femur.

Step 8: Ream in 1-mm increments until there is chatter and then in 0.5-mm increments. Ream to 10.5 mm for the 8.5-mm nail, 12.5 mm for the 10.7-mm nail and to 14.5 mm for the 12.5-mm nail. For the 8.5-mm nail, ream the upper part of the bone to 11 mm. For trochanteric entry, it may be helpful to ream an extra millimeter in the upper part of the bone to allow lower resistance passage of the nail as it goes around the bend.

Step 9: Prepare the nail for insertion. With PRECICE 1, choose and assemble the insertion end type (trochanteric, piriformis, retrograde, tibial) and lengths. The mechanism comes in one length, while the final nail length depends on the length of the insertion end chosen. With the new PRECICE 2, the nail is not modular and one must choose the length of the entire nail in advance.

Step 10: Apply the proximal targeting device and test its alignment to the screw holes by inserting the drill guides and drill bits.

Step 11: Place the nail under the beam of the image intensifier to confirm that the mechanism is not predistracted. Save this image for reference.

Step 12: Remove the beaded guide wire used for reaming as the nail is not cannulated. Insert the nail into the canal up to the level of the planned osteotomy (drill holes).

Step 13: Have one assistant lift the foot off the table. Have the other assistant lift the proximal end of the nail using the insertion guide. The two assistants are applying an extension moment to the femur to prevent displacement of the femur during the osteotomy.

Step 14: Use a sharp 6–8 mm osteotome to osteotomize the femur through the 1-cm lateral incision. The femur will easily break through the six drill holes. Listen for the break and once it occurs withdraw the osteotome. Test that the femur is fractured by moving the femur gently into varus and valgus and watching it move using live fluoroscopy. Maintain the extension moment throughout this test.

Step 15: Once the break is confirmed to be complete, advance the nail by gently hammering on the impactor until

the nail crosses the osteotomy line into the distal (antegrade nailing) or proximal (retrograde nailing) segment of the femur. The extension moment is no longer needed to stabilize the femur. Advance the nail until the upper end is at the level of the base of the piriformis fossa or just inside the greater trochanter for piriformis and trochanteric nails, respectively. For retrograde nails, make sure that the end of the nail is inside the femur at the intercondylar notch.

Step 16: Lock the nail proximally (antegrade) and distally (retrograde) with two screws using the locking guide. For distal locking screws (antegrade) and proximal locking screws (retrograde), my personal technique preference is to insert a long 1.8-mm wire into the locking hole, followed by a 3.5-mm cannulated drill for the 8.5-mm nail, 3.8-mm cannulated drill for 10.7-mm nails and a 4.8-mm cannulated drill for the 12.5-mm nail. In the 12.5-mm nail, overdrill with a solid 5-mm drill bit and in the 10.7-mm nail overdrill with a solid 4-mm drill bit.

Step 17: Lock the nail distally with two lateral-medial screws. Do not use anteroposterior middle screw because it can act as a stress riser for fracture of the femur.

Step 18: Insert the end cap into the proximal part of the nail for antegrade nails only.

Step 20: Close all the incisions.

Step 21: Insert the ERC device into a sterile sleeve. Mark out the level of the magnet on the skin using fluoroscopy. Apply the ERC directly over the magnetic spindle using the image intensifier to mark out the magnet. Face the ERC distally for antegrade nails and proximally for retrograde nails. It takes 7 min to lengthen the femur 1 mm.

Step 22: Check if the distraction gap is seen radiographically and compare it to the predistracted space (FIGURE 4). If an objective increase in space is seen the procedure is completed. If not, do a second millimeter of distraction to confirm. In the rare case where the bone does not separate, the nail must be extracted and tested on the bench and if it does not distract then replaced with another nail. An incomplete osteotomy can cause a failure of distraction.

#### *Surgical technique tibia*

Step 1: Mark the proximal and distal end of the nail as before.

Step 2: Mark the level of the osteotomy as before. In the tibia, err on the side of a more proximal osteotomy for better bone formation.

Step 3: Make a single unicortical drill hole anteriorly at the level of the tibial osteotomy. A second unicortical drill hole can be made on the medial surface. Avoid getting into the anterior and deep posterior compartments. Multiple drill holes are not made prior to reaming to avoid extrusion of reamings into the deep posterior and anterior compartments, this minimizing the risk of a compartment syndrome.

Step 4: Insert a guide wire from the distal fibula to the tibia. This wire should be inclined from distal on the fibula to proximal on the tibia. Incise the skin on the tibial side and drill over the wire with a 3.2-mm drill bit across both bones. Insert a solid 4.5-mm screw from the tibia to the fibula such that the

head of the screw is on the tibial side. The screw should always be oriented so that the tibial side is more proximal than the fibular side.

Step 5: Perform a mid-diaphyseal fibular osteotomy through a small posterolateral incision between the superficial posterior and lateral muscle compartments.

Step 6: To get the starting point, insert a Steinmann pin into the proximal tibia at the level of the joint in line with the medial tibial spine on the AP and at the joint line on the lateral view. The starting point is usually medial to the patellar tendon.

Step 7: Ream the tibia in 1-mm increments until there is chatter and then in 0.5-mm increments as for the femur.

Step 8: After reaming, add multiple drill holes to the planned osteotomy level in the tibia. Using a sharp osteotome, complete the osteotomy through the anterior incision in a percutaneous fashion.

Step 9: Once the osteotomy is confirmed to be complete, insert and advance the PRECICE tibial nail until the upper end is below the level of the bone.

Step 10: Drill the first proximal locking screw from antero-medial to posterolateral aiming for the head of the fibula: upper locking screw hole on the left and lower locking screw hole on the right. Measure a locking screw long enough to fixate the tibia to the proximal fibula. Lock the second proximal locking screw from the anterolateral side into the tibia only. If the first drill hole and screw misses the fibula, then lock the fibula with a separate 4.5-mm screw using a wire followed by a cannulated drill from the tibia to the fibula.

Step 11: Free hand lock two of the three distal screws leaving either the middle or distal one empty.

Step 12: Perform a distraction test of 1 mm using the ERC (FIGURE 4).

#### Postoperative procedures

The ERC is placed firmly but comfortably over the area where the magnet of the PRECICE implant is located. The implant is distracted to the desired amount as viewed on the ERC display screen. Radiographs should be obtained every 2 weeks to monitor the progress of the lengthening and to confirm that the amount of lengthening performed has been achieved. The radiographs also monitor the quality of the regenerate. While 1 mm/day is generally recommended, clinical and radiographic examination may show that lengthening should progress at a faster or slower pace (FIGURE 4). Unilateral lengthening patients are instructed on partial weight-bearing restrictions using a walker and then progressing to crutches. They are taught to judge weight-bearing using a bathroom scale. Weight-bearing is restricted to 22 kg (50 lbs) for the 8.5- and 10.7-mm nails and 34 kg (75 lbs) for the 12.5-mm PRECICE 2 nail (P2). For the original PRECICE (now referred to as P1), the restriction was always 22 kg (50 lbs). Bilateral lengthening cases, with 12.5-mm P2 devices are taught to walk using a walker and to place up to 68 kg (150 lbs) when standing on both legs and 34 kg (75 lbs) on each leg during single leg stance of walking.

Similarly, bilateral 8.5- or 10.7-mm P2 cases are taught to walk with a walker and place up to 45 kg (100 lbs) when standing on both legs and 22 kg (50 lbs) during single leg stance of walking. Bilateral cases are also transitioned to crutches from a walker. All patients are given a wheelchair to use for longer distances.

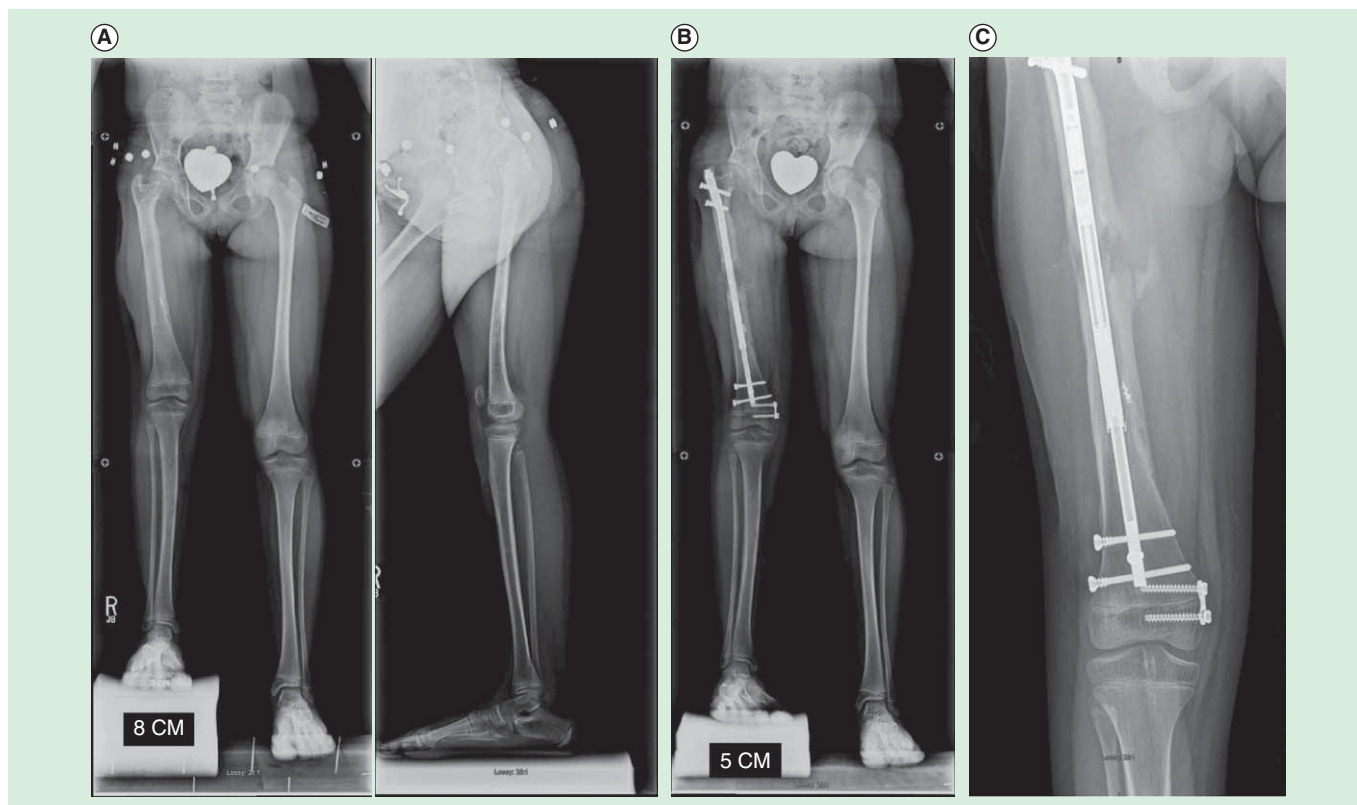
#### Cost-effectiveness

No studies have been performed on the cost-effectiveness of PRECICE. The PRECICE implant is priced competitively and comparably with other limb lengthening external fixation devices such as the Taylor Spatial Frame (Smith and Nephew Orthopedics, Memphis, TN, USA). The PRECICE device may even be cheaper than the combination of implants used in techniques such as Lengthening over Nail, Lengthening and then Nailing, etc. [17]. Reduction in device- and pin-related complications should lead to a greater cost-effectiveness of this device compared to external fixation. For example, external fixation lengthening has a significant rate of unplanned secondary procedure to treat device-related complications such as deep pin infections and loosening, axial deviation, muscle contractures related to transfixation by wires or pins, etc. [18]. Therefore, reduction in unplanned secondary surgery will significantly increase the cost-effectiveness of the PRECICE method.

#### Clinical profile & postmarketing findings

Lengthening in children & adults for leg length discrepancy & stature

Paley *et al.* (2013) conducted a retrospective, single-center study to report the early results of the PRECICE system, based on the experience of three surgeons at a single center [19]. Institutional Review Board approval was obtained for this study. The results were first presented at the EPOS Annual Meeting on April 2013 in Athens, Greece, and then at POSNA in Toronto, Canada. This study was recently published [20]. The authors reviewed the results of 48 consecutive patients (65 PRECICE nails) implanted between 12/1/2011 and 12/4/2012 (all PRECICE 1). The mean age of the patients in this series was 25.6 years (10.3–58.4 years). Lengthening for congenital discrepancy (FIGURE 5) was performed in 23 patients; mean age was 18.5 years (10.3–43.7 years) and mean pre-operative lengthening goal was 4.91 cm (1.5–6.5 cm), while the preoperative mean LLD was 6.27 cm (1.5–18.2 cm). The lengthening rate was 0.8 mm/day. The goals of lengthening were met in all except five patients in this group; mean lengthening was 4.5 cm (0.5–6.5 cm) (FIGURES 6 & 7). Lengthening for developmental discrepancy was performed in four patients; mean age was 17.8 years (13–27 years) and mean preoperative lengthening goal was 3.68 cm (1.5–6.5 cm). The lengthening rate was 1 mm/day. The mean lengthening was 3.68 cm (1.5–6.5 cm). All patients achieved the preoperative lengthening goal without any complication. Lengthening for posttraumatic limb length discrepancies (FIGURE 8) was carried out in six patients; mean pre-operative goal was 3.48 cm (1.7–5.0 cm) and mean age was



**Figure 5. Eight year old girl with congenital femoral deficiency. (A)** Preoperative AP and lateral radiographs. She had been previously treated by a superhip-superknee surgery and has also successfully undergone one external fixator lengthening at age 4. Her leg length discrepancy was 7 cms. **(B)** AP radiograph after 5cms of lengthening by Precice2 8.5mm x 245mm, trochanteric entry femoral nail. Her genu valgum was treated at the same time by a hemi-epiphysiodesis plate. **(C)** This AP radiograph during the consolidation phase shows the distraction gap filling in with bone one month after stopping distraction.

49.0 years (30–58 years). The lengthening rate was 0.93 mm/day. The mean lengthening was 3.48 cm (1.7–5.0 cm). All patients achieved the preoperative lengthening goal without any complication. In addition to this, 15 patients underwent stature lengthening either for achondroplasia (FIGURE 9) or for cosmetic reasons (FIGURE 10). Their mean age was 29.7 years (15–48 years), baseline height was 166.2 cm (150–177 cm) and the preoperative goal of lengthening was 5.64 cm (3.0–6.5 cm). The lengthening rate was 1 mm/day. The mean lengthening was 4.63 cm (2.7–6.5 cm). Eight patients electively stopped lengthening before reaching their preoperative goal due to personal reasons and not due to medical reasons.

The mean length gained was 4.41 cm (range, 0.5–6.5 cm), with a mean distraction rate for all nail segments of 0.83 mm/day (range, 0.50–1.11 mm/day). Three patients required a bone grafting procedure for failed regenerate (all congenital). Three nails broke in two patients during the consolidation phase. All three had ignored the weight-bearing restrictions and had stopped using crutches. Each was exchanged for a locked standard intramedullary nail and length was preserved in each case. Each nail that broke fractured at the proximal (2) or middle (1) weld of the first-generation PRECICE nail.

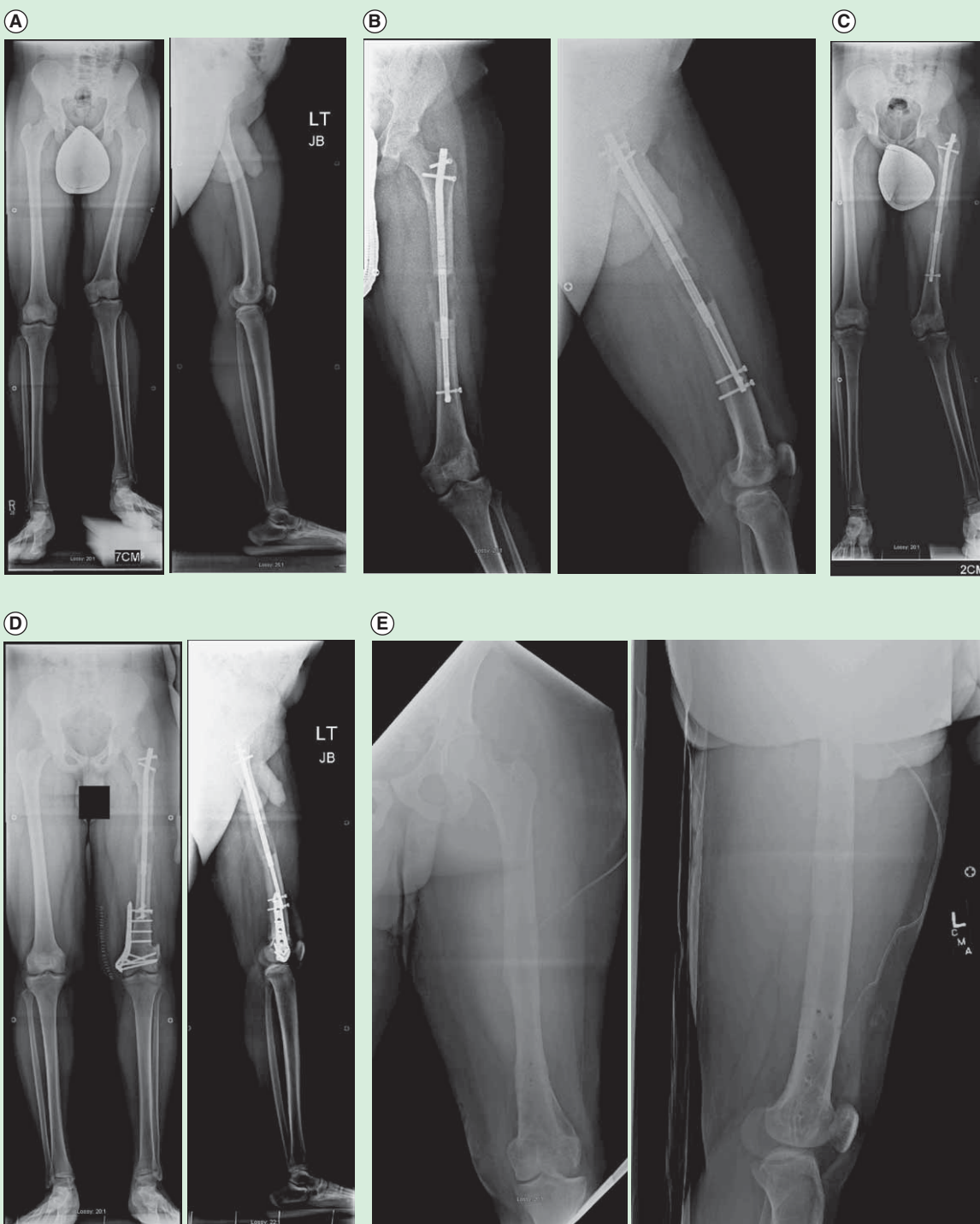
Seven nails in six patients ceased to lengthen during the distraction phase. Two of these were due to operator error in

applying the ERC device in the wrong direction, leading to breakage of the mechanism. These two were replaced and lengthened uneventfully. In the other five, mechanism breakage is thought to have occurred due to lengthening against a dense regenerate or premature consolidation. All nails that ceased to lengthen were in males with large muscular thighs. The nails were replaced in four. The mean length achieved was 4.73 cm (4.1–5.5 cm) in these four nails.

Mean healing time and return to full weight-bearing was 125.3 days (range, 52–262 days). In total, there were 18 unplanned surgeries in 16 patients. The remaining patients successfully completed treatment without any complication. The authors concluded that PRECICE demonstrated excellent rate control and accuracy. The bidirectional feature proved useful in one subject who was acutely shortened 2 cm in conjunction with treatment of a seroma, followed by resumption of gradual lengthening 2 weeks later.

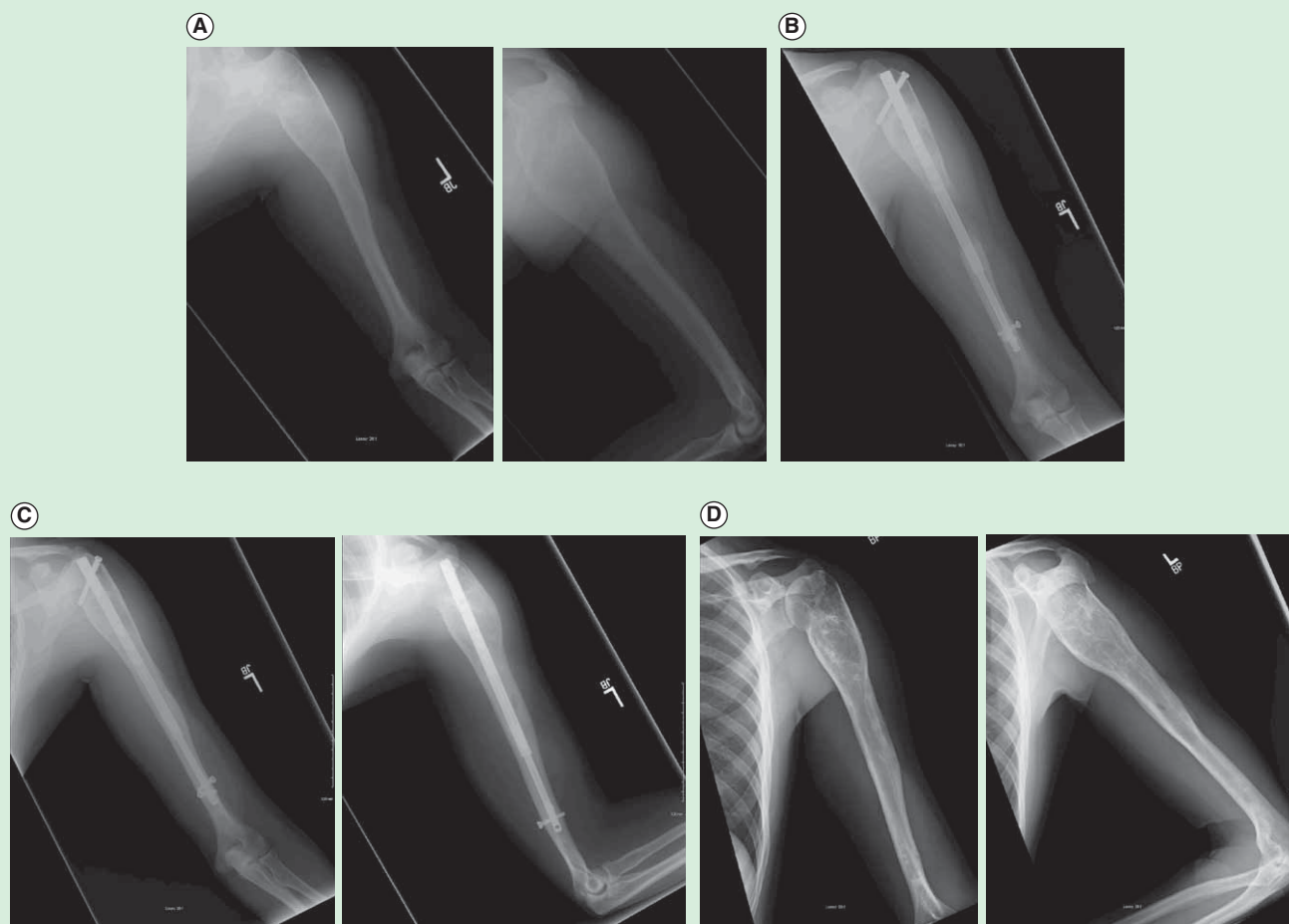
Limb lengthening in children with a new, controllable, internal device

Herzenberg *et al.* (2013) conducted a retrospective, single-center study to report preliminary results of the PRECICE system in children [21,22]. The results were presented at the EPOS Annual Meeting on April 2013 in Athens, Greece. The authors



**Figure 6. Sixteen year old boy with a leg length discrepancy and valgus deformity secondary to a partial growth arrest of the distal femur (developmental etiology).** (A) Preoperative AP and lateral radiographs (B) AP and lateral radiographs after 6.5cms lengthening using a 10.7mms trochanteric entry Precice1 tibial nail (we used a tibial nail since at the time the trochanteric entry femoral nail was unavailable; the current P2 tibial nail has a shorter magnet and would not be a good choice to use but the P1 tibial nail had the regular length magnet and could be used in the femur). This was our very first Precice case in December 2011. (C) AP radiograph showing the worsened valgus deformity after 6.5cms of lengthening. (D) AP and lateral radiographs after acute correction of the valgus deformity by a medial closing wedge osteotomy with internal fixation using a locking plate. A peroneal nerve decompression was also done to minimize the risk of nerve stretch injury. (E) The final AP and lateral radiographs after removal of all of the hardware a year later.





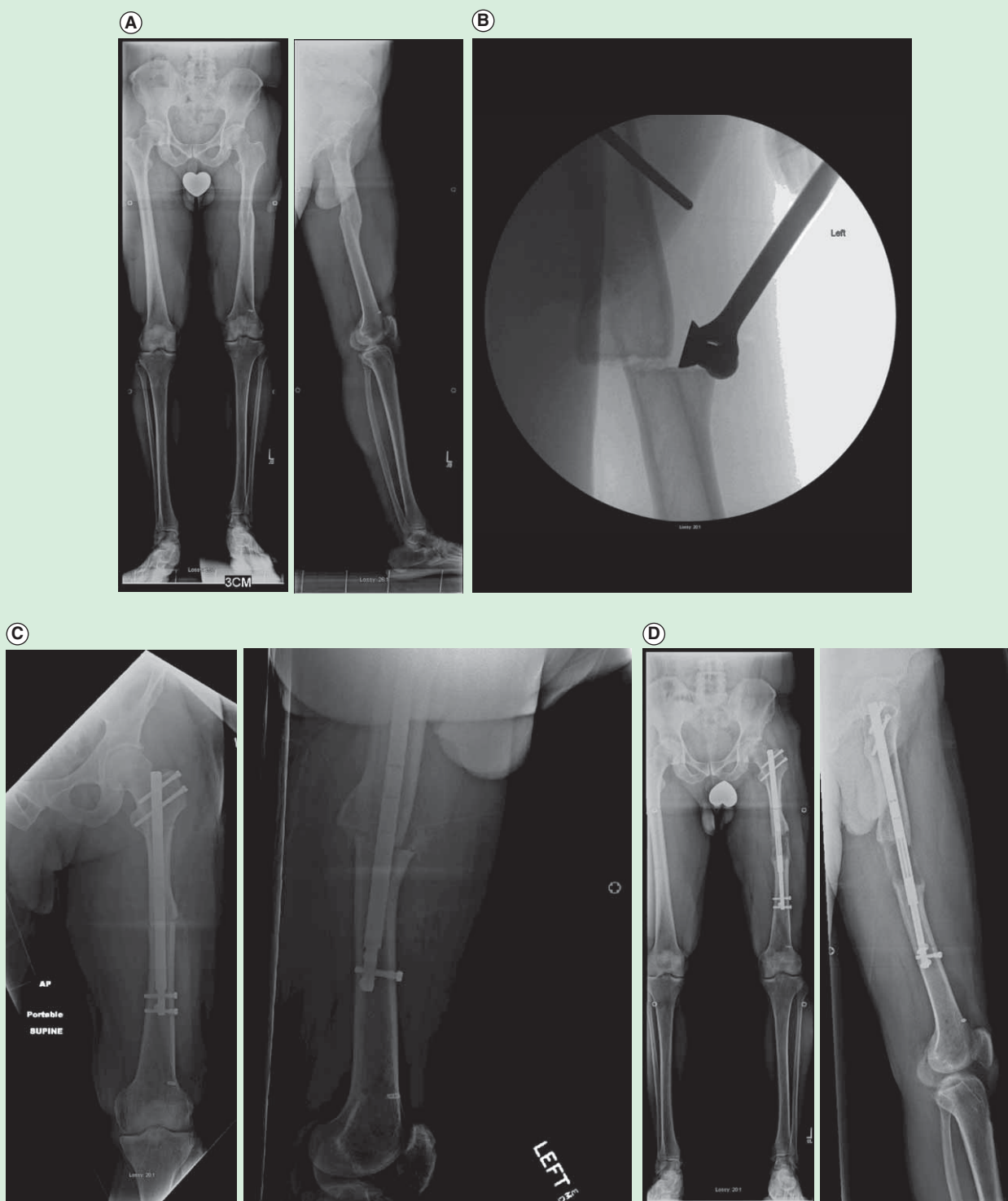
**Figure 7. Arm shortening (6.5 cms) due to growth arrest from a unicameral bone cyst. (A)** Preoperative AP and Lateral radiographs of left humerus **(B)** AP radiograph at the end of 6.5cms distraction using a 10.7mm Precice1 femoral piriformis entry nail. **(C)** AP and lateral radiographs after three months of consolidation. There is excellent bony bridging. **(D)** The nail was removed one year later. The bone and previous cyst are well consolidated.

reviewed 20 children of various etiologies who underwent implant between January 2012 and March 2013. Mean subject age was 13.5 years (range, 7–16 years). Mean target lengthening was 5.2 cm (range, 2.5–6.5 cm). Subjects who underwent lengthening with external fixation as well as with the PRECICE system were sent questionnaires and asked to compare their experience.

At the time of the meeting, 20 of 27 limbs completed lengthening. Target lengths programmed into the ERC closely matched radiographic measurements (average of 5.2 vs 5.6 cm, respectively). Range of motion (ROM) was well maintained throughout the lengthening and consolidation phases. Of the 16 patients who were completely healed, the average distraction index was 2.4 cm/month (range, 1.2–3.25 cm/month) and the average healing index was 1.12 months/cm (range, 0.46–2.0 months/cm). Three complications were observed and resolved: one prominent screw treated with revision, one peroneal nerve entrapment treated with decompression and one rotary subluxation treated with ligament reconstruction. Nine of the 13 children who had prior lengthening with external fixation

completed a questionnaire comparing their experience with internal and external fixation. All reported that PRECICE allowed for easier physical therapy, better cosmetic results and a higher rate of overall satisfaction. When asked which device they would choose if another surgery was needed, all nine patients said that they would choose the PRECICE system. The authors concluded that the device is accurate, allows for good ROM, results in few complications and is an attractive alternative to external fixation. More patients and long-term follow-up are still needed.

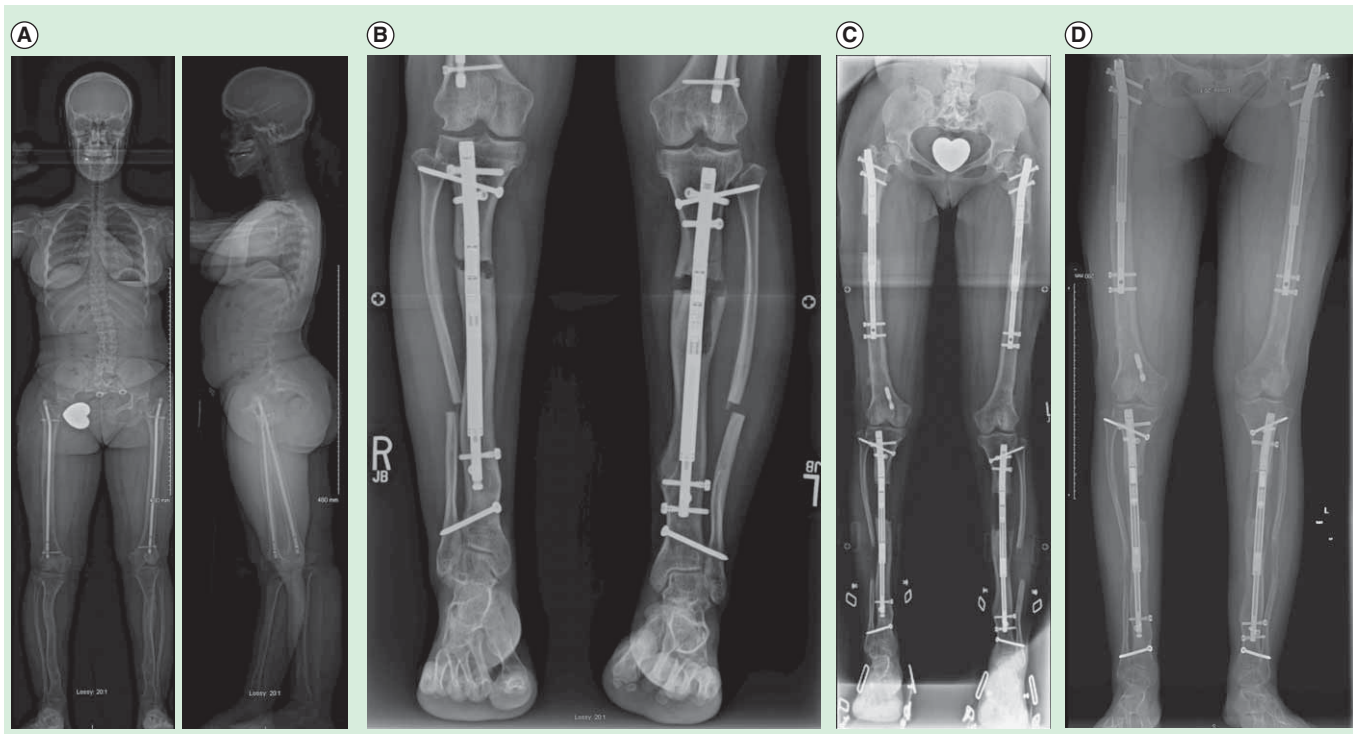
Precision of the new remote controlled internal lengthening nail Kirane *et al.* (2013) conducted a retrospective, single-center study to evaluate the clinical efficacy of the PRECICE system. The results were presented at the Hospital for Special Surgery Research Symposium in June 2013 in New York, NY [23]. The authors reviewed 10 femur and seven tibia lengthening cases using the PRECICE system. Medical records were reviewed for etiology, patient characteristics, surgery details, distraction process, bone alignment, adjacent joint ROM and any



**Figure 8.** Forty-eight year old man with a symptomatic post-traumatic 5 cms LLD of the femur. **(A)** Preoperative AP and lateral radiographs of the femur. **(B)** Using fixator assistance, the osteotomy was made prior to reaming in order to realign the medullary canals of the previously bayonet deformity. **(C)** AP and lateral radiographs after insertion of Precice1 12.5 mms nail. The bayonet deformity is reduced. **(D)** AP and lateral radiographs after 5cms of lengthening. Good bone healing is seen. He proceeded to heal completely.

complications. Distraction distance measurements were done at every follow-up visit using a calibrated digital radiology system (PACS, OnePacs LLC, New York, NY, USA).

The results indicated that at 13.5 weeks follow-up (range, 4–30 weeks), the lengthening was 33.65 mm (range, 14–61 mm) with an accuracy of  $100.7 \pm 0.23\%$ . All femur



**Figure 9.** Sixteen year old girl with achondroplasia who had undergone 2 previous lower limb (combined femur and tibia 4 segment lengthening) and one bilateral humeral lengthening. **(A)** Preoperative standing EOS scan radiographs. **(B)** Bilateral tibial lengthening was carried out using Precice1 10.7mm tibial nails. **(C)** Two weeks later she underwent removal of the previous femoral nails and insertion of bilateral 10.7 mm Precice1 trochanteric entry nails. Both femurs were lengthened 6.5 cms and tibias 5 cms simultaneously. The staggered nail insertion was to avoid reaming all four bones at the same time because of the risk of fat embolism. **(D)** The patient is now 62 inches (158 cms) tall.

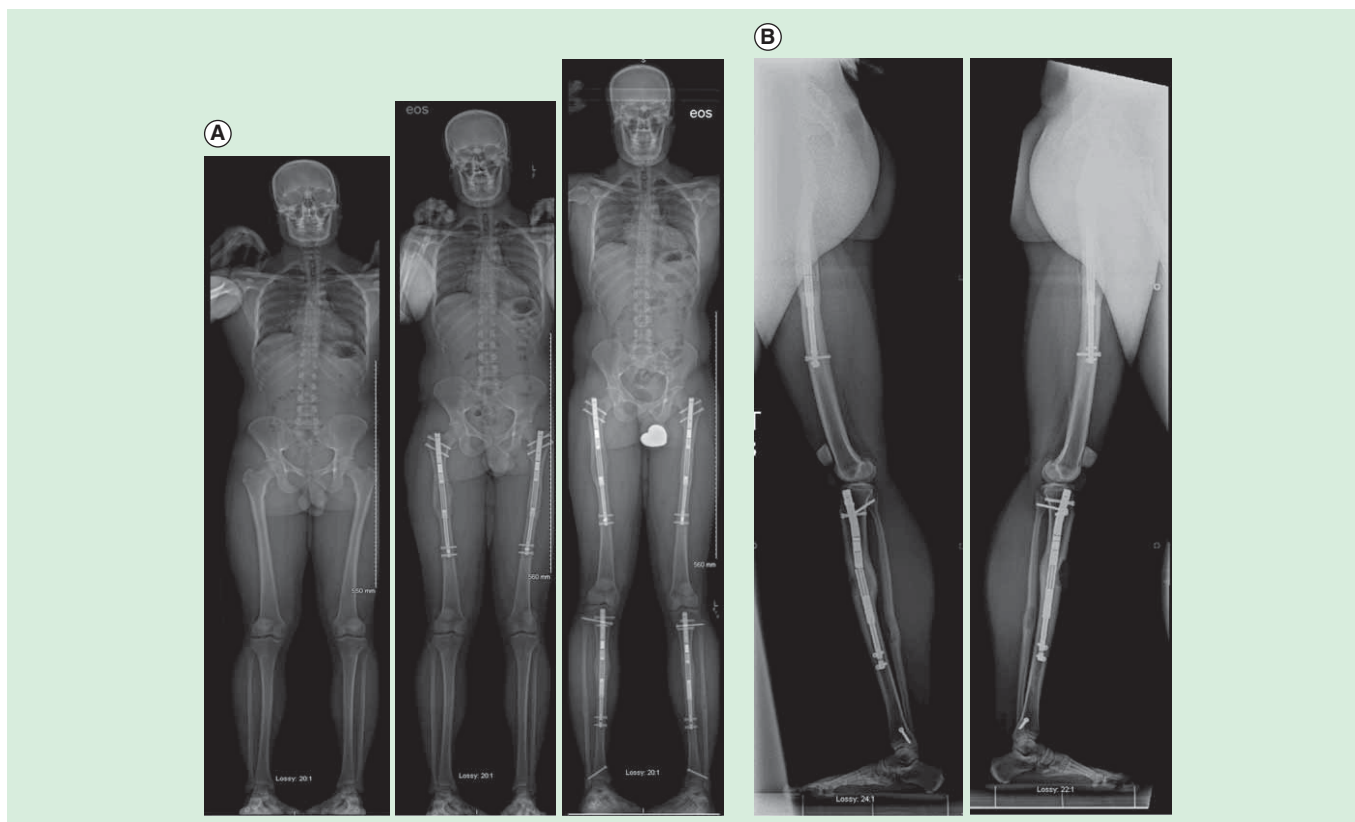
cases had excellent bone healing, while two tibia cases required insertion of bone marrow concentrate for delayed bone healing. There were no implant failures or major complications. The authors concluded that the new PRECICE internal lengthening nails have an accuracy of distraction close to 100%. The use of an external magnetic controller was straightforward and easy to explain to patients. Notably, there were no implant failures in this initial series. In several patients, realignment of the pre-existing deformity was possible through an osteotomy at the apex of the deformity. Furthermore, the hip, knee and ankle ROM were well maintained. Iliotibial band release and gastrocnemius recession were helpful in maintaining knee and ankle ROM, respectively, during lengthening. Tibia lengthening was associated with more difficulties than femur lengthening. Additionally, a tendency of varus-procurvatum deformity of the femur and valgus-procurvatum deformity of the tibia was successfully prevented by inserting blocking screws into the concavity of the potential deformity. Lastly, consideration must be given to the length of the thicker nail segment beyond the osteotomy to ensure adequate stability and to prevent iatrogenic deformities.

Internal lengthening device for congenital femoral deficiency & fibular hemimelia

Shabtai *et al.* (2014) reported a prospective, nonrandomized, single-center study to evaluate the PRECICE system in terms

of healing index, complications, accuracy of the device's external controller and adjacent-joint ROM [24]. Institutional Review Board approval was obtained prior to performing any study-related procedures. Sixty six subjects were enrolled and treated for congenital limb shortening between January 2012 and May 2013. Of these, 21 were treated using the PRECICE system and 18 met the eligibility criteria for analysis of the PRECICE system. Ten females and eight males were enrolled with a mean age of 19 years. Sixteen femurs and five tibias were lengthened with a mean of 4.4 cm (range, 2.1–6.5 cm). Mean distraction index was 1.0 mm/day (range, 0.5–1.8 mm/day). Healing index complications, device accuracy and ROM were recorded.

At the time of the publication, 10 of the 21 devices had been removed. This was typically done 12–24 months after insertion when the bone was solidly healed on all four cortices. Mean healing index was 0.91 months/cm (range, 0.2–2.0 months/cm). There were seven complications requiring an additional unplanned surgery, including one hip flexion contracture, three femurs with delayed healing, one tibia with delayed healing, one hip subluxation/dislocation and one knee subluxation. The external controller was accurate as programmed and actual lengthening amounts were consistent. ROMs of the hip, knee and ankle were essentially maintained. The authors concluded that the intramedullary implant of the



**Figure 10. Cosmetic stature lengthening. (A)** Three EOS scan AP radiographs (left), after bilateral femoral lengthening (6.5 cms) using Precice1 12.5 mms piriformis entry nails (middle), and after bilateral tibial lengthening (4.5 cms) using Precice1 10.7 mms tibial nails (left). The total height increase was 11 cms. **(B)** Long lateral radiographs of both femurs and tibias show that there is a deficiency in the anterior bone formation of the left tibia compensated by hypertrophic regenerate bone formation posteriorly. On the right there is a break in the Precice 1 nail through one of the welds. This break occurred due to delay in regenerate bone formation and resumption of weight-bearing. Fortunately, the bone healed with minimal procurvatum deformation of the tibia.

device allows for satisfactory joint motion during treatment in most patients. Lengthening was achieved in an accurate, controlled manner and all patients reached their goal length. Complications remain a concern as is the case with all approaches in this complex patient population.

Precision of the PRECICE internal bone lengthening nail

Kirane *et al.* (2014) reported a retrospective, single-center study to evaluate the PRECICE system in terms of accuracy and precision of distraction, effects on bone alignment, effects on adjacent-joint ROM, and frequency of implant-related and non-implant-related complications [25]. Twenty four patients were reviewed who underwent femoral and/or tibial lengthening procedures using the PRECICE nail from August 2012 to July 2013 for conditions of varied etiology. At each postoperative visit, the accuracy and precision of distraction, bone alignment, joint ROM and any complications were recorded. Accuracy reflected how close the measured lengthening was to the prescribed distraction at each postoperative visit, while precision reflected how close the repeated measurements were to each other over the course of the total lengthening period. No patients were lost to follow-up.

Minimum follow-up from surgery was 3 weeks (mean 14 weeks; range, 3–29 weeks).

The results indicated that mean total lengthening was 35 mm (range, 14–65 mm), with an accuracy of 96% and a precision of 86%. All patients achieved target lengthening with minimal unintentional side effects on bone alignment. The knee and ankle ROMs were minimally affected. Of the complications requiring return to the operating room for an additional surgical procedure, there was one (4%) implant failure caused by a nonfunctional distraction mechanism and six (24%) non-implant-related complications, including premature consolidation in one patient (4%), delayed bone healing in two (8%), delayed equinus contracture in two (8%) and toe clawing in one (4%). The authors concluded that the PRECICE system is a valid option to achieve accurate and precise limb lengthening to treat a variety of conditions with limb shortening or length discrepancy.

How precise is PRECICE compared to ISKD in intramedullary limb lengthening?

Schiedel *et al.* (2014) reported a prospective, nonrandomized, single-center study to evaluate the reliability and safety of the

**Table 1. Alternative devices and intended use.**

Device	Manufacturer	Intended use	Distraction mechanism	Materials	Device status
Albizzia/Guichet	DePuy Orthopedics	For limb lengthening of the tibia and femur	Mechanical telescoping, gear actuation	Stainless steel	CE Mark, not approved in the USA
Fitbone	Wittenstein GmbH	For limb lengthening of the tibia and femur	Motorized, radiofrequency powered telescoping, gear actuation	Titanium alloy	CE Mark, not approved in the USA
ISKD	Orthofix Inc.	For limb lengthening of the tibia and femur	Mechanical telescoping, gear actuation	Titanium alloy	CE Mark, recalled in the USA

first generation of the PRECICE system [26]. Institutional Review Board approval was obtained prior to performing any study-related procedures. Twenty four patients with 26 PRECICE nails were enrolled and implanted between June 2012 and March 2013. Anteroposterior radiographs of the leg while the patient was standing were obtained before surgery, every 14 days during lengthening and during or after consolidation. The occurrence of any problems, obstacles and complications was recorded after lengthening was completed. The Paley classification was used for comparison with other lengthening procedures and external lengthening procedures. Preliminary results were compared with the known difficulties in the use of mechanical lengthening devices such as ISKD.

The results showed that two nails did not function properly, yielding 24 of the 26 nails implanted that lengthened over the desired distance. Lengthening desired was 38 mm and lengthening obtained was 37 mm. There were two nail breakages, one occurring in the welding seam and one due to an accidental fall by the patient during consolidation. In total, 15 problems, five obstacles and four complications were observed throughout treatment of the study cohort. The authors concluded that the mean accuracy of lengthening with PRECICE, 97%, is similar to that in the comparable ISKD study (96%) [26], and that continuing improvements to the system by the manufacturer, including the recent release of the second-generation system, will address the issues observed in this study.

### Alternative devices

The use of limb lengthening instruments is a well-known technique in the treatment of lower limb discrepancies. TABLE 1 lists other implantable limb lengthening devices described in the literature. The indication/intended use statements are gathered from the literature and other publically available sources of information, such as company web sites.

Published reports on Albizzia, ISKD and Fitbone report a wide variety of problems and complications. Simpson *et al.* reported that seven of their 33 (21.2%) ISKD nails were classified as runaway implants [8]. This meant that the rate of distraction could not be controlled in 21.2% of patients and exceeded the desired lengthening rate. A total of 15/33 (45.4%) of their nails experienced rate control complications, with seven lengthening too quickly and another seven being

overly difficult to lengthen. Elsewhere in the literature, we can find reports of ISKD nails that lengthened at rates much greater than 1 mm/day or were classified as runaway nails ranging from 9% (1/11, Kubiak) to 18.9% (7/37, Kenaway) to 83.3% (10/12) in the series by Mahboubian *et al.* (Hankemeier) [27–30]. Wang *et al.* reports that five of their 16 nails lengthened uncontrollably, forcing them to ask these patients to modify their weight-bearing and activity level from week to week based on the rate of distraction of the nail. If it were distracting too slowly, they would be asked to increase their weight-bearing and to become more active, and vice versa (Wang, Simpson) [31,32]. At best, this was a very imperfect way of controlling the rate of distraction of ISKD. There are additional series that further detail runaway nail rates that range from 9% (Kubiak) to 20% (Paley) [27,33]. The article by the ISKD's designer (Cole) reviewed his initial series of 20 nails in 18 patients [34]. They reported lengthening rates of up to 1.7 mm/day, but no mention is made as to how many patients lengthened at such a rapid rate. In an unpublished study by Paley, of 350 ISKD lengthenings, distraction rates of up to 5 mm/day were documented.

A large majority of patients with runaway nails went on to develop poor regenerate or nonunion at the distraction site. While the article by Cole *et al.* observed zero nonunions or patients who required a later bone graft procedure, other articles document rates of runaway nails requiring additional surgery in the form of either bone grafting or exchange nailing that range from 20% (Wang 1/5, Kenaway 5/7 to Simpson 6/7) to 86% [8,28,31].

Certainly, poor regenerate formation/nonunion is not exclusive to intramedullary nails that fail to maintain safe rate control, but rather this remains a well-known complication for all limb lengthening procedures. While only 1/5 of the runaway nails in the article by Wang *et al.* required later bone grafting, a total of six out of their 16 ISKDs (37.5%) required an additional surgery to treat poor regenerate or nonunion [31]. Simpson needed to treat only 6/8 (75%) of his runaway nails with additional surgery, although, a total of 8/33 (24.2%) nails ultimately required this approach [8]. Five of the seven (71.4%) runaway nails in Kenaway's series required bone graft and/or exchange nailing, along with an additional three nails that similarly developed deficient bone healing, for a total of 8/37 (21.6%) [28]. Singh *et al.* reported that 3/24 (12.5%) of

their Fitbone nail segments required later bone grafting, and Baumgart *et al.* saw that 1/12 (8.3%) Fitbone segments need additional surgery to achieve adequate healing [3,34].

Kenaway *et al.* found a significant association between poor regenerate and age of patients greater than 30, total lengthening greater than 4 cm, smoking and a distraction rate greater than 1.5 mm/day [28].

One risk that has been reported to be a predisposing factor to poor regenerate is a distraction rate greater than 1.5 mm/day (Kenaway) [28]. This is entirely avoided with the PRECICE nail. In comparison to the results listed above, Paley *et al.* reported that only three of 65 implant segments went on to develop poor regenerate of nonunion that necessitated an additional bone grafting surgery.

Another well-reported problem with implantable lengthening nails is difficulty with distraction. Kubiak *et al.* attributed this to impingement and friction secondary to a straight nail attempting to lengthen a curved femur as well as compressive forces caused by the soft tissues that are substantial enough to limit lengthening. This complication is still the most frequent one with the Albizzia nail. Failure to distract can be related to wear of the teeth of the internal ratchet gear or due to the inability of the patient to turn the limb the full 20 degrees due to pain. Similarly with ISKD, some patients have too much pain to rotate the femur the 3–9 degrees needed. Manipulation by the surgeon in the office to manipulation under epidural or other anesthesia has been used to treat this problem. Botox injection into the quadriceps to reduce muscle spasm is also useful. Incidence of failure to distract with ISKD varies from 0% (Cole) to 64% (Kubiak), of whom 6/7 of the patients in that series required a return to the operating room [27,33]. Similarly, the Simpson series had a rate of 24.2% (8/33) of ISKD nails that were difficult to distract, and 75% (6/8) of those needed a return to the operating room [8].

Paley *et al.* reported seven cases of PRECICE with failure to distract. One bilateral case occurred due to user error. The others occurred due to resistance from abundant callus and large thigh musculature. It is likely that the failure of the mechanism occurred after repeated lengthening attempts against the force of a nearly prematurely consolidated bone. Since the mechanism was changed in PRECICE 1 (May 2013) and since the introduction of PRECICE 2 which contains the new mechanism, there have been no further failures of distraction in over 150 cases [PALEY D, PERS. COMM.].

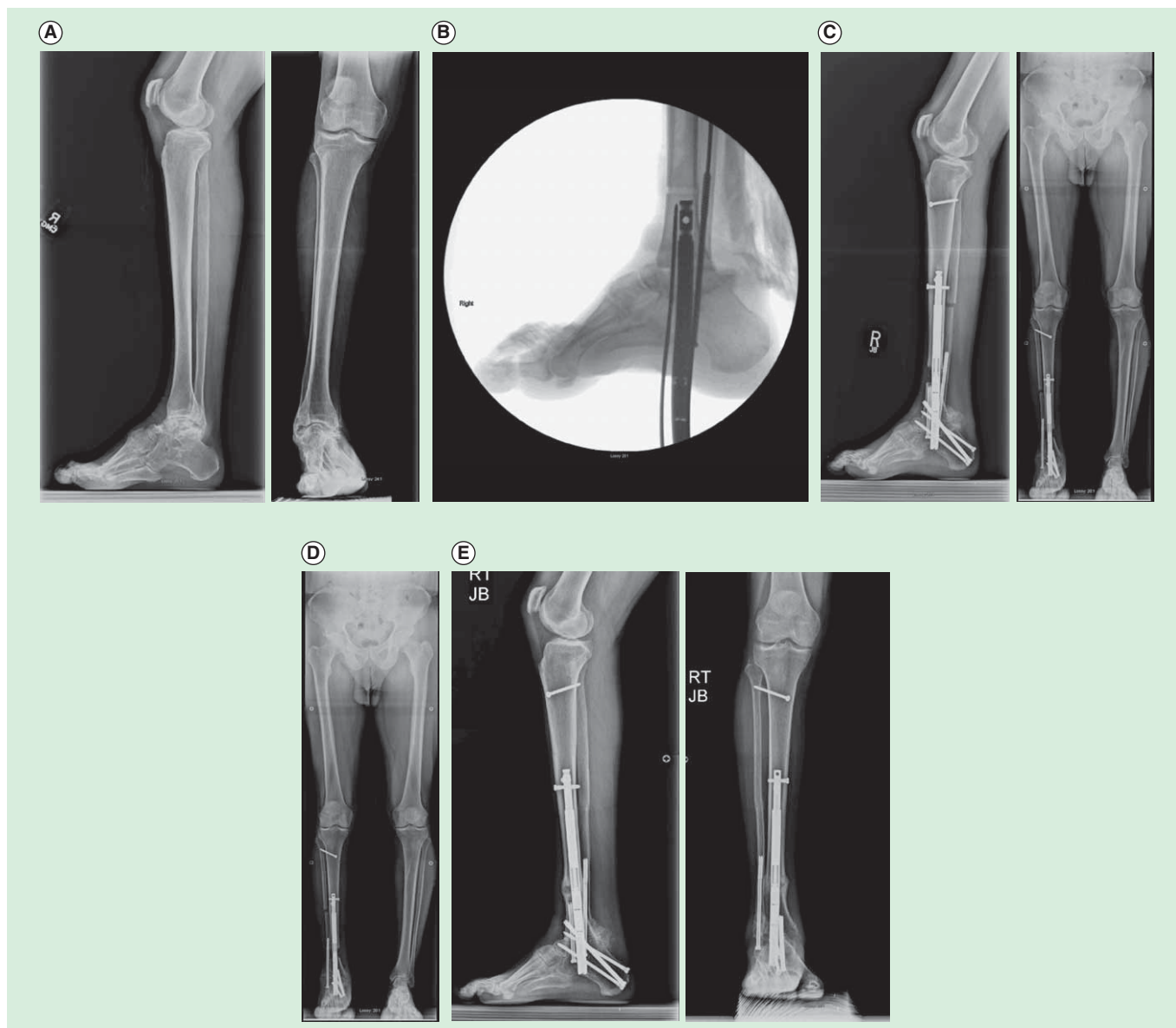
Mechanical failure of other implantable nails can be divided into two groups: mechanical failure of the distraction mechanism and breakage of the integrity of the nail itself. In the Baumgart *et al.* series of 12 cases, two patients required reoperation for failure of mechanism [34]. There were no nail breakages in this series. In a Fitbone series of 24 nails, two patients had to have exchange nails to larger diameter Fitbone nails as the gears were too weak for distraction. Both these patients had congenital deformities (Singh *et al.*) [3]. Another Fitbone cohort of eight patients reported one

mechanism failure and one nail breakage; both were also congenital etiologies (Krieg *et al.*) [35]. The ISKD initial series (20 nails) reported two hardware failures; both nails broke with patients fully weight-bearing and at the junction of the proximal and distal components. Design changes were made in the nail and authors claimed no further breakages. This further stresses the importance of *in vivo* analysis of these devices and appropriate engineering adjustments to improve product design. No mention of mechanism failure was noted in this series (Cole *et al.*) [33]. Another review of 57 ISKD nails revealed no nail breakages; however, three failures of the lengthening mechanism occurred. One required an exchange nail with an examination of the failed nail showing a jammed ratchet mechanism. The other two nails required manipulation another anesthesia. One nail acutely lengthened 3 cm instead of 3 mm despite external monitoring, again illustrating the unpredictability of the ISKD (Kenaway *et al.*) [28]. In the largest ISKD series of 242 devices, 15 (6.2%) experienced mechanical failure. Ten of these failures were nail fractures, two of which were in the same patient undergoing stature lengthening. Most fractures were in the male component; however, other areas of nail were prone to failure as well. The remaining five nails failed at the lengthening mechanism, two of which failed due to assembly error (Burghardt *et al.*) [34]. Ensuring the functionality of the nail during surgery, as in our surgical protocol, would circumvent these types of complications. In 41 Albizzia nail insertions, three failures were related to the distraction mechanism and one to nail fracture, all requiring reoperation (Guichet *et al.*) [35].

Among 10 patients (24 nails) with the Fitbone device, two patients (20%) did not reach the anticipated length due to restricted knee movement. Both these patients were undergoing stature lengthening and had femoral and tibial lengthening (Singh *et al.*) [3]. In a smaller series (eight patients) using the same device, they achieved 93% (83–100%) planned length. However, two of the eight patients were eliminated from this analysis due to nail failure (Krieg *et al.*) [35].

Using the ISKD nail lengthening of 33 limbs resulted in 32 achieving desired goals. However, eight patients (eight limbs) required additional procedures (manipulation, fixator-assisted) to achieve this due to slow or no progression of distraction (Simpson *et al.* 2009) [8]. Baumgart's cohort of 12 patients attained complete length objectives in all patients [2]. Interestingly, all these patients received unilateral lengthening, which eliminates many factors that may cause premature termination. Similar to our series most of these terminations were in the bilateral group. Nevertheless, internal devices in previous and in our current series seem to have a good track record for obtaining desired lengths.

Pain is an important consideration with every lengthening method. Pain is an expected part of lengthening. The degree of pain does vary between external and internal fixation methods. Pin sites and pin infections as well as tethering of muscles and other soft tissues are believed to be a major cause



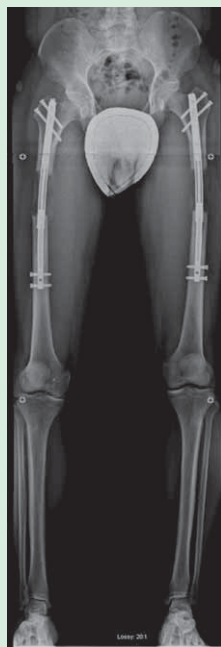**Figure 11. Fifty five year old man with ankle arthritis and pain. (A)** Preoperative AP and lateral radiographs of the tibia, ankle and foot. **(B)** Intra-operative fluoroscopic picture of a lateral of the foot showing the ankle fusion and retrograde insertion of the first Precice2 in the US November 2013. **(C)** The distal tibia was lengthened 2.5 cm. **(D)** The ankle was fused and LLD equalized intentionally leaving a 1 cm discrepancy. **(E)** AP and lateral radiographs showing union of the ankle fusion and the distraction gap.

of pain during lengthening with external fixation. Since all of these are absent with implantable devices, the pain is related to stability, rate of distraction, physical therapy and stretch of soft tissues. While it is not possible to eliminate stretch, control of rate and stability of fixation is device dependent. Friction may also play a part and can be limited by the type of reamers used (straight vs flexible), amount of overreaming as well as by the level of osteotomy (at apex of curvature of femur; leaving as short an amount of nail to drag on the moving segment).

Pain is a major factor with Albizzia and ISKD. Both of these devices rotate through the callus. Such rotation leads to friction and muscle spasm pain. This type of pain has been notably

absent from reports on Fitbone and from the experience with PRECICE.

Using devices that require no rotation such as the motorized Fitbone, there was minimum to no pain on distraction (Singh *et al.*) [3]. However, of the 10 patients, who had 24 implants, only two achieved 60 mm. The rest were between 27 and 50 mm, with a mean of 40 mm/nail. In contrast, of the 31 patients using the Albizzia nail, all experienced discomfort or pain during lengthening. Twelve patients (39%) required readmission to perform ratcheting under a general anesthetic (Guichet *et al.*) [36]. PRECICE patients seem to have minimal to no pain during lengthening.



**Figure 12. AP radiograph of bilateral femoral lengthening seen during an 8-cm cosmetic stature lengthening.** This went on to heal uneventfully. The mild varus neutralizes the valgus deviation that is associated with lengthening along the anatomic axis. The concern is mostly regarding the risks of nail breakage. Strict weight-bearing precautions should accompany any bilateral lengthening and especially if bowing is seen.

### Status of the device

The first generation of the PRECICE system was granted CE Mark in September 2010 and FDA 510(k) clearance in July 2011 for limb lengthening of the femur or tibia. The PRECICE 2 system received CE Mark in May 2013 and FDA 510(k) clearance in October 2013. Commercial use of the PRECICE system began internationally and in the USA in 2011. The PRECICE 2 received FDA clearance in October 2013. Its clinical use in the USA began in November 2013 (FIGURE 11).


### PRECICE 2

In 2012, in response to preliminary results of breakage through the welds and failure to distract in some cases (Paley *et al.*, EPOS, POSNA) [20], Ellipse Technologies together with Paley began a redesign of the nail housing to eliminate the welds as well as a redesign of the nail mechanism to increase its ability to distract against resistance (FIGURES 5 & 11). The mechanism problem was solved first but modifying the coupling between the drive shaft and the gears. Previously, the powerful torque strength of the rotating magnet could break this connection if it met too much resistance. The new mechanism is protected against this and is now three-times stronger in distraction strength. The tibial models have been loaded with a smaller magnet to prevent from overtorquing the magnet due to the

closer proximity of the ERC to the magnet in the tibia. Consequently, PRECICE 2 tibial nails should not be used in the femur since there would not be enough strength to turn the smaller magnet with the ERC at larger distances from the magnet. The new mechanism had its debut in May 2013 with a retrofit of all PRECICE 1. The newer mechanism has performed perfectly with no documented cases of failure to distract to date. At our center alone, over 150 nails with the new mechanism have been implanted and lengthened successfully to date.

The elimination of the welds has also greatly strengthened the nail. Laboratory testing has shown that the weld-less PRECICE 2 nail is four-times stronger for bending strength and three-times stronger for axial loading than the original nail. To date, with over 250 of these PRECICE 2 nails implanted there have been only two reports of nail breakage. One was my own patient who was undergoing a congenital femoral lengthening after a previous knee fusion. This 18-year-old young man chose to ignore all weight-bearing restrictions after a unilateral 8-cm lengthening. His nail broke the external shell at the distal telescopic junction. Angulation occurred without any loss of length. The nail was successfully exchanged for a trauma locking nail 3 days after the failure. One European tibial nail broke through the proximal locking screw hole. After review of that case, it was evident to me that the nail was inserted too anteriorly leading to poor support from the surrounding bone. Furthermore, there was a blocking screw inserted at the level of the break. Since titanium is very notch sensitive, slight notching of the nail by the blocking screw at the level of the locking hole with a very proximal tibial osteotomy set up the nail for failure. Surgeon error is more at fault in this case. Weight-bearing restrictions are essential to the use of this nail. They have been increased to 75 lbs during the distraction phase for the 12.5-mm PRECICE 2 from only 50 lbs for the 12.5-mm PRECICE 1. These should be adjusted downwards when additional factors add to the load on the nail as is illustrated in the two failure cases. PRECICE 2 seems to have eliminated the two main device failure mechanisms that were identified with PRECICE 1. The company has been very responsive and implemented these changes in record time. One observation made by Paley is that some nails showed a varus bowing of the nail in some femoral lengthenings (FIGURE 12). This has not led to any failure to distract or to any significant deformity or breakage. It may be related to the nail being made of titanium. This is especially in bilateral application where patients may be weight-bearing more than allowed. One solution would be changing the material of the nail to a stiffer alloy such as cobalt-chrome. In 2014 some fragmentation of the end of the outer tube of the nail has been noted. The end of the larger diameter of the nail is slotted at four places and mated and welded to a crown that has 4 ridges to provide anti-rotation stability to the telescopic nail. The fins between the slots are the sight of fragmentation of the end





**Figure 13. Photographs of two nails removed from a patient who underwent bilateral femoral lengthening.** There is a crown breakage on the right femur nail with propagation of cracks up from the nail slots (left side of figure) while the crown and slots remain intact on the nail from the left femur (right side of figure) (A). The P2 nail anti-rotation mechanism uses four female ‘thru-slots’ in the distal end of the proximal nail tube mating with the crown’s four male ridges, and secured with tacking welds after assembly (B). The new P.1 anti-rotation feature is machined into the inner diameter of the distal end of the proximal nail tube without breaking through to the surface and without requiring welds (C).

of the nail tube. Breakages of this crown and fins have been identified in some cases including this patient (FIGURE 13). In two cases it has been linked to breakage of the nail. It is also contributing to the bowing of the nail. To strengthen the nail and avoid crown failures, in December 2014, Ellipse Technologies released the P2.1 which has a modified keying feature without ‘thru-slots’ or tack welds (FIGURE 13).

### Conclusion

PRECICE is the newest generation implantable limb lengthening device and the first CE-marked and FDA-cleared device to have both forward and reverse length adjustment capability. It had demonstrated excellent rate control. This is the most important factor for achieving good results with any limb lengthening. The reverse mechanism although not often used is very helpful when it is needed. It can be used to close down a distraction gap when there is failed bone formation, or nerve irritation or palsy. It can also be used to dynamize the regenerate bone (compression-distraction) when there is delayed consolidation (accordion maneuver). The reduction in size of the implant down to 8.5-mm diameter as well as the reduction in length of the device down to 195 mm makes PRECICE applicable to pediatric femurs as young as 7 years

of age. The improvement in strength of the nail and the mechanism have also made it more reliable, allowing for weight-bearing.

### Expert commentary

Implantable limb lengthening is the natural progression for limb lengthening technology. Since I got involved with limb lengthening in 1985, we have witnessed an evolution of techniques related directly and indirectly to limb lengthening [37–39]. The gold standard external fixation device has advanced with circular fixators being computer controlled and automated [39], monolateral fixators having hinges and spanning joints. Meanwhile, the implantable lengthening devices have struggled to get FDA approval. Early devices such as Bliskunov, Albizzia and Fitbone developed in Europe as early as the 80s and 90s have never got FDA clearance. Therefore, the FDA clearance (510k) of the Orthofix ISKD in 2001 was a landmark event. Unfortunately, the lack of rate control and pain issues dampened the initial enthusiasm with this device. The FDA clearance of PRECICE in 2011 represented the next major milestone for implantable devices. The appearance of this device on the market will probably soon be followed by other such devices. PRECICE

however has raised the bar. To compete, a device will have to demonstrate excellent rate control, forward and reverse capability, sufficient strength of the mechanism to resist the large forces of the regenerate bone and musculature, and sufficient strength to allow partial weight-bearing without breakage of the implant.

**Five-year view**

Bliskunov first introduced implantable limb lengthening in 1983 (over 30 years ago). Therefore, the use of implantable lengthening devices is still in its infancy. As PRECICE is the first limb lengthening nail to have forward and reverse capability, it is fair to call it the first second-generation implantable limb lengthening device. The first-generation devices were ones that can only lengthen and distract but not shorten and compress. Thus far, the indications for implantable lengthening have only been for lengthening of long bones and for distraction of the spine for the treatment of scoliosis [35]. The gold standard of distraction is the external fixator. The external fixator is able to apply distraction for many other indications. These include treatment of bone defects by bone transport, treatment of deformity by asymmetric distraction, treatment of nonunions by compression-distraction, etc. The next 5 years will see a plethora of new

remote controlled implantable devices and a wide variety of drive mechanisms. We anticipate a bone transport nail, a bone lengthening plate, an angular deformity plate, a trauma nail that can correct mal-rotation and length, a nonunion device that can compress-distract, implantable articulated distraction of joints and joint contractures, etc. Currently, size is a major limiting factor. External fixators or external cable-driven implants are the only way to apply distraction technology to smaller bones such as in small children, forearm, hand and foot, and cranio-maxillo-facial bones. The next 5 years will see miniaturization of remote control implant technology.

**Acknowledgements**

*The author wishes to thank C Hafner from Ellipse Technologies for his help in the research and preparation of this manuscript.*

**Financial & competing interests disclosure**

*D Paley is a paid consultant for Ellipse Technologies and also receive royalties on this device. The author has no relevant affiliations or financial involvement with any organization or entity with a financial interest in or financial conflict with the subject matter or materials discussed in the manuscript. This includes employment, consultancies, honoraria, stock ownership or options, expert testimony, grants or patents received or pending, or royalties.*

**Key issues**

- Implantable distraction technology is reliable in producing distraction osteogenesis of bone and distraction histogenesis of soft tissues.
- PRECICE is the first forward and reverse remote controlled implant for bone lengthening.
- PRECICE has excellent efficacy and rate control and reduces the pain of limb lengthening compared to external fixation.
- PRECICE reduces device-related complications seen with external fixation.
- Miniaturization of diameter and length has made it useable in smaller long bones such as the humerus, small patients such as children and dwarfism.
- PRECICE is the first second-generation implantable lengthening device.
- Many new applications and devices are expected over the next 5 years.

**References**

Papers of special note have been highlighted as:

- of interest
- of considerable interest

1. Cheung KM, Cheung JP, Samartzis D, et al. Magnetically controlled growing rods for severe spinal curvature in young children: a prospective case series. *Lancet* 2012;379(9830):1967-74
2. Baumgart R, Betz A, Schweiberer L. A fully implantable motorized intramedullary nail for limb lengthening and bone transport. *Clin Orthop Rel Res* 1997;343:135-43
3. Singh S, Lahiri A, Iqbal M. The results of limb lengthening by callus distraction using an extending intramedullary nail (Fitbone) in non-traumatic disorders. *J Bone Joint Surg Br* 2006;88:938-42
4. Baumgart R, Betz A, Schweiberer L. A fully implantable motorized intramedullary nail for limb lengthening and bone transport. *Clin Orthop Rel Res* 1997;343:135-43
5. Krieg AH, Speth BM, Foster BK. Leg lengthening with a motorized nail in adolescents: an alternative to external fixators? *Clin Orthop Rel Res* 1994;14:352-7
6. Young N, Bell DF, Anthony A. Pediatric pain patterns during Ilizarov treatment of limb length discrepancy and angular deformity. *J Pediatr Orthop* 1994;14:352-35
7. Garcia-Ciembrelo E, Olsen B, Ruiz-Yague M, et al. Ilizarov technique: result and difficulties. *Clin Orthop Rel Res* 1992;283:116-23
8. Simpson AH, Shalaby H, Kennan G. Femoral lengthening with the intramedullary skeletal kinetic distractor. *J Bone Joint Surg Br* 2009;91:955-61
9. Sabharwal S, Rozbruch SR. What's new in limb lengthening and deformity correction? *J Bone Joint Surg Am* 2011;93:2323-232
10. Gross RH. Leg length discrepancy: how much is too much? *Orthopedics* 1978;1:307-10
11. Torode IP, Gillespie R. Classification and management of congenital abnormalities of

Expert Review of Medical Devices Downloaded from informahealthcare.com by 73.46.221.27 on 02/18/15 For personal use only.

- the femur. *J Bone Joint Surg Br* 1983;65: 557-68
12. Kalamachi A, Cowell HR, Kim KI. Congenital deficiency of the femur. *J Pediatr Orthop* 1991;11:90-4
  13. Pappas AM. Congenital abnormalities of the femur and related lower extremity malformations: classification and treatment. *J Pediatr Orthop* 1983;3:45-60
  14. Boakes JL, Stevens PM, Moseley RF. Treatment of genu valgus deformity in congenital absence of the fibula. *J Pediatr Orthop* 1991;11:721-4
  15. Froster UG, Baird PA. Congenital defects of lower limbs and associated malformations: a population based study. *Am J Med Genet* 1993;45:60-4
  16. Rogala EJ, Wynne-Davies R, Littlejohn A, Gormley J. Congenital limb abnormalities: frequency and aetiological factors: data from the Edinburgh Register of the Newborn (1964-68). *J Med Genet* 1974;11:221-33
  17. Paley D, Herzenberg JE, Paremain G, Bhav A. Femoral lengthening over an intramedullary nail. A matched-case comparison with Ilizarov femoral lengthening. *J Bone Joint Surg Am* 1997; 79(10):1464-80
  18. Paley D. Problems, obstacles, and complications of limb lengthening by the Ilizarov technique. *Clin Orthop Rel Res* 1990;250:81-104
  - **This is the first study to classify and categorize complications of limb lengthening according to their level of significance.**
  19. Paley D, Harris M, Debiparshad K, Prince D. Limb lengthening by implantable limb lengthening devices. *Techniques in Orthopaedics* 2014;29(2):72-85
  - **This is the first and largest clinical series of PRECICE lengthenings studied and published. It also presents the technique as well as the complications well.**
  20. Harris M, Paley D, Prince D. New implantable lengthening nail. Presented at: EPOS Annual Meeting. Athens, Greece. April 2013
  21. Herzenberg JE, Specht SC, Standard SC, Conway JD. Limb lengthening with a new internal magnetic device for post-traumatic injury. Presented at: AAOS/OTA/SOMOS/ORS Extremity War Injuries VIII: sequelae of Combat Injuries Research Symposium. Washington, DC, USA. February 2013
  22. Herzenberg JE, Specht SC, Standard SC. Limb lengthening in children with a new, controllable, internal device. Presented at: EPOS Annual Meeting. Athens, Greece. April 2013
  23. Kirane Y, Fragomen A, Rozbruch SR. Precision of the new remote controlled internal lengthening nail. Presented at: HSS Research Symposium. New York, NY. June 2013
  - **This study confirms the reliability and efficacy of the PRECICE mechanism especially with regard to rate.**
  24. Shabtai L, Specht SC, Standard SC, Herzenberg JE. Internal lengthening device for congenital femoral deficiency and fibular hemimelia. *Clin Orthop Relat Res* 2014; 472(12):3860-8
  - **This study demonstrates that excellent results can be achieved with PRECICE even when lengthening for congenital leg length discrepancy.**
  25. Kirane YM, Fragomen AT, Rozbruch SR. Precision of the PRECICE® Internal bone lengthening nail. *Clin Orthop Relat Res* 2014;472(12):3869-78
  26. Schiedel FM, Vogt B, Tretow HL, et al. How precise is the PRECICE compared to ISKD in intramedullary limb lengthening? *Acta Orthop* 2014;85(3):293-8
  27. Kubiak E, Strauss E, Grant A, et al. Early complications encountered using a self-lengthening intramedullary nail for the correction of limb length inequality. *Jt Dis Relat Surg* 2007;18:52-7
  28. Kenaway M, Krettek C, Lioudakis E, et al. Insufficient bone regenerate after intramedullary femoral lengthening: risk factors and classification system. *Clin Orthop Rel Res* 2010;469:264-73
  29. Mahboubian S, Seah M, Fragomen AT, Rozbruch SR. Femoral lengthening with lengthening over a nail has fewer complications than intramedullary skeletal kinetic distraction. *Clin Orthop Rel Res* 2012;470:1221-31
  30. Hankmeier S, Pape HC, Gosling T, et al. Improved comfort in lower limb lengthening with the intramedullary skeletal kinetic distractor. Principles and preliminary clinical experiences. *Arch Orthop Trauma Surg* 2004;124:129-33
  31. Wang K, Edwards E. Intramedullary skeletal kinetic distractor in the treatment of leg length discrepancy – A review of 16 cases and analysis of complications. *J Orthop Trauma* 2012;26(9):138-44
  32. Simpson AH, Kenwright J. Fracture after distraction osteogenesis. *J Bone Joint Surg Br* 2000;82:659-65
  33. Burghardt RD, Herzenberg JE, Specht SC, Paley D. Mechanical failure of the intramedullary skeletal distractor in limb lengthening. *J Bone Joint Surg Br* 2011;93: 639-43
  34. Cole JD, Justin D, Kasparis T, et al. The intramedullary skeletal kinetic distractor (ISKD) : first clinical results of a new intramedullary nail for lengthening of the femur and tibia. *Injury* 2001;32(suppl 4): SD129-39
  35. Krieg AH, Speth BM, Foster BK. Leg lengthening with a motorized nail in adolescents: an alternative to external fixators? *Clin Orthop Rel Res* 2008;466: 189-97
  36. Guichet JM, Deromedis B, Donnan LT, et al. Gradual femoral lengthening with the Albizzia nail. *J Bone Joint Surg Am* 2003;85:838-48
  37. Paley D. Progress in and from Limb Lengthening. In: *Current Progress in Orthopedics*. Tree Life Media, India; 2014
  38. Burghardt RD, Paley D, Specht SC, Herzenberg JE. The effect on mechanical axis deviation of femoral lengthening with an intramedullary telescopic nail. *J Bone Joint Surg Br* 2012;94(9):1241-5
  39. Kirane Y, Fragomen A, Rozbruch R. Precision of the PRECICE internal bone lengthening nail. *Clin Orthop Relat Res* 2014;472(12):3869-78

This article may include discussion of both on and off-label uses of our products. Please note that this study may have limitations whether it be the study-size, endpoints, lack of randomization, period of follow-up, etc. Discussion in this article may also provide only anecdotal information. This article may be the result of company-sponsored research or grants provided to physicians who conducted the research on their own. Some authors may be consultants to Ellipse-Tech, others are not. The reader should understand these limitations before reading them and critically review all these sources of information.

The FDA-cleared intended use for PRECICE is as follows:

*The Ellipse Technologies PRECICE Intramedullary Limb Lengthening System is indicated for limb lengthening of the tibia or femur. Please see the full prescribing information (IFU) for the contraindications, side effects, warnings and precautions.*